

## Catheter Ablation of Ventricular Tachycardia Roderick Tung, Noel G. Boyle and Kalyanam Shivkumar

*Circulation*. 2010;122:e389-e391

doi: 10.1161/CIRCULATIONAHA.110.963371

*Circulation* is published by the American Heart Association, 7272 Greenville Avenue, Dallas, TX 75231

Copyright © 2010 American Heart Association, Inc. All rights reserved.

Print ISSN: 0009-7322. Online ISSN: 1524-4539

The online version of this article, along with updated information and services, is located on the  
World Wide Web at:

<http://circ.ahajournals.org/content/122/3/e389>

**Permissions:** Requests for permissions to reproduce figures, tables, or portions of articles originally published in *Circulation* can be obtained via RightsLink, a service of the Copyright Clearance Center, not the Editorial Office. Once the online version of the published article for which permission is being requested is located, click Request Permissions in the middle column of the Web page under Services. Further information about this process is available in the [Permissions and Rights Question and Answer](#) document.

**Reprints:** Information about reprints can be found online at:  
<http://www.lww.com/reprints>

**Subscriptions:** Information about subscribing to *Circulation* is online at:  
<http://circ.ahajournals.org/subscriptions/>

## Catheter Ablation of Ventricular Tachycardia

Roderick Tung, MD; Noel G. Boyle, MD, PhD; Kalyanam Shivkumar, MD, PhD

Ventricular tachycardia (VT) is an abnormal rapid heart rhythm originating from the lower pumping chambers of the heart (ventricles). The normal heart usually beats between 60 and 100 times per minute, with the atria contracting first, followed by the ventricles in a synchronized fashion. In VT, the ventricles beat at a rapid rate, typically from 120 to 300 beats per minute, and are no longer coordinated with the atria.

The controlled contraction of the ventricles is important for the heart to pump blood to the brain and the rest of the body and to maintain a normal blood pressure. Abnormal and fast rhythms from the ventricle may impair the ability of the pump to supply blood to the brain and the rest of the body as a result of the rapid rate and weak contractions. This may result in palpitations (a feeling of rapid or abnormal heart beat), dizziness, lightheadedness, or syncope (loss of consciousness). If the heart rate increases to more than 300 beats per minute and becomes totally uncoordinated, this is usually called ventricular fibrillation (VF), which will cause sudden cardiac death.

VT occurs most commonly in patients with weakened heart muscle (cardiomyopathy) or when scar tissue develops in the heart. In patients with coronary artery disease (blockage of blood vessels on the surface of the heart), this scar is the result of a prior heart attack (myocardial infarction) when the muscle dies as a result of a blockage in blood flow. Scar, or fibrosis, can interfere with the normal electrical impulse in the heart, leading to a short-circuiting of the rhythm, called reentry. VT can also occur in patients with normal hearts by a different mechanism whereby the electric conduction is overly excitable, like a muscle twitch.

Sudden cardiac death causes about 450 000 fatalities each year in the United States alone. It is most commonly caused by VT deteriorating into VF, which is fatal within a few minutes if not defibrillated (shocked) back to a normal rhythm. (Figure 1A) Defibrillation may be accomplished by an automated external defibrillator or an implantable cardioverter-defibrillator (ICD). It is important to distinguish VT and VF, which are electric problems of the heart, from a heart attack, which is due to the sudden blockage of an artery. Heart attacks are treated with clot-busting drugs, balloon angioplasty, or stents. Sometimes, VT and VF are seen in that

setting and are treated with electric shocks and drugs. The treatment of abnormal rhythms is discussed below.

### Treatment Options

There are 3 treatment options for VT, although many patients require a combination: an ICD, antiarrhythmic medications, or catheter ablation. Many patients at risk for VT are treated with an ICD. This is the most effective method of restoring a potentially life-threatening rhythm such as VT or VF back to a normal rhythm. However, an ICD does nothing to prevent the heart from going into VT. The ICD is a “safety net” and is like having an ambulance crew accompany you 24 hours a day.

Antiarrhythmic medications that modify the conduction of the electric impulse of the heart can be effective in suppressing VT. These medications can reduce the risk of recurrence by 75% but have potential side effects that include proarrhythmia, or worsening of the heart rhythm. For this reason, initiation of antiarrhythmic agents often requires close monitoring. Amiodarone, the most effective drug, has many side effects, which can involve toxicity to the vital organs like the liver, thyroid, lungs, eyes, and skin. Because of the discomfort associated with frequent ICD shocks and the side effects of antiarrhythmic drugs, catheter ablation is an important additional treatment option for many patients already using these therapies.

### Catheter Ablation Therapy

Catheter ablation has been used to treat heart rhythm disorders for more than 25 years. This procedure targets the origin of the VT by placing a long, thin wire or catheter into the heart chambers through the veins of the leg. When areas that are critical to the arrhythmia are identified, a localized delivery of radiofrequency energy is applied, which produces a small burn about 4 to 5 mm in diameter.<sup>1</sup> The number of burns required to treat the VT varies among patients. In patients with scar tissue in the heart, ablations may be performed within the scar and around its perimeter to cauterize or ablate the abnormal electric circuit responsible for the VT (Figure 1B).

---

The information contained in this *Circulation* Cardiology Patient Page is not a substitute for medical advice, and the American Heart Association recommends consultation with your doctor or healthcare professional.

From the Cardiac Arrhythmia Center, Ronald Reagan UCLA Medical Center, David Geffen School of Medicine at the University of California, Los Angeles.

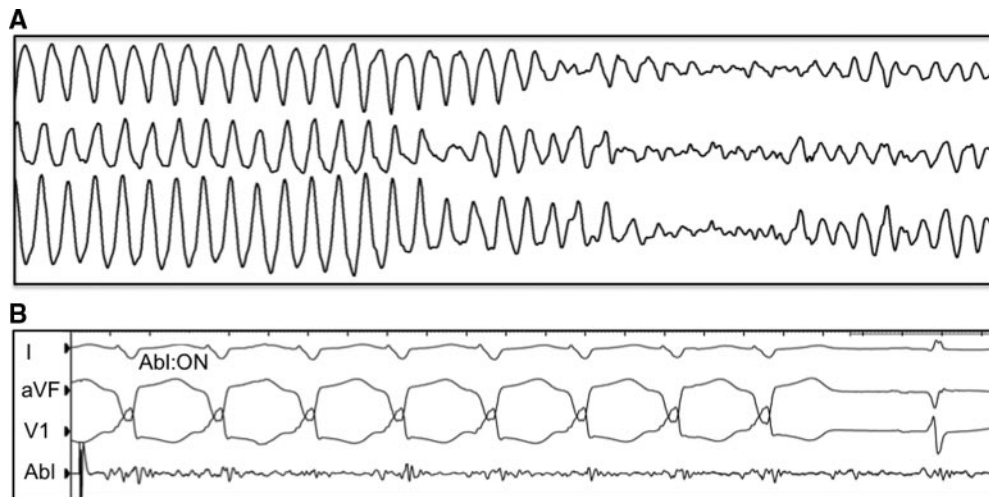
Correspondence to Kalyanam Shivkumar, MD, PhD, UCLA Cardiac Arrhythmia Center, David Geffen School of Medicine at UCLA, 47-123 CHS, 10833 Le Conte Ave, Los Angeles, CA 90095-1679. E-mail kshivkumar@mednet.ucla.edu

(*Circulation*. 2010;122:e389-e391.)

© 2010 American Heart Association, Inc.

*Circulation* is available at <http://circ.ahajournals.org>

DOI: 10.1161/CIRCULATIONAHA.110.963371



**Figure 1.** A, VT often deteriorates into VF, a lethal heart rhythm. B, Ablation of VT. Radiofrequency ablation is delivered (Abl:ON) at a site determined by mapping. The VT stops after 2 seconds of burning, and normal heart rhythm is restored.

### What to Expect Before and After Ablation

Before the procedure, special cardiac imaging with computed tomography scan or echocardiography is usually performed to assess the location of scarring, if any, in the heart. Immediately before the procedure, a transesophageal echocardiogram may be performed to exclude the presence of blood clots in the heart. Additionally, echocardiography helps to assess the overall pumping function of the heart. Magnetic resonance imaging is traditionally contraindicated in patients with an ICD but can be performed at experienced centers under close supervision.

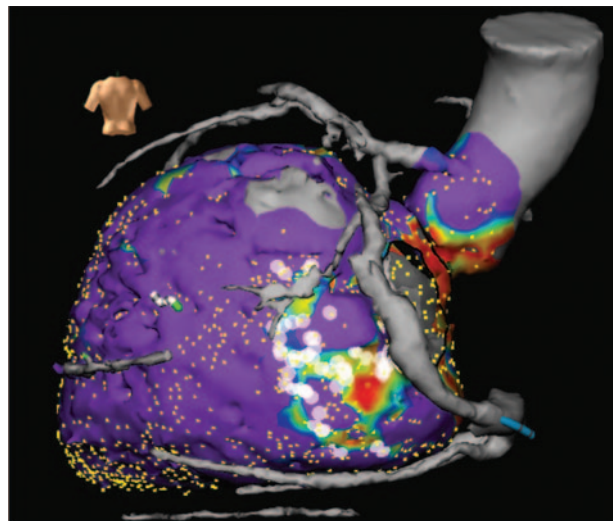
Precautions are taken to prevent the formation of blood clots before, during, and after ablation. During the procedure, an intravenous blood thinner called heparin is administered. After the procedure, many patients will continue taking warfarin, an oral anticoagulant, for up to a month to prevent blood clot formation when the heart is healing from the ablation. A short-acting injectable blood thinner, known as low-molecular-weight heparin, is often used for the first several days because warfarin requires 5 to 10 days to become completely effective.

The procedure is usually performed under deep sedation or general anesthesia to minimize patient discomfort and movement. The catheters are inserted through intravenous ports, or sheaths, placed in the veins in the groin and sometimes through a vein on the side of the neck. To access the left ventricle, a needle may be used to create a small puncture in the wall between the right and left sides of the heart under ultrasound guidance (called transseptal catheterization). Alternatively, a catheter can be inserted into the heart through an artery in the groin (similar to heart catheterization procedures). The ablation catheter is moved around the ventricle, and a virtual 3-dimensional image of the heart is created with a computer mapping system that acts like a navigation system (Figure 2). The location of the catheter is determined by use of fluoroscopy (x-ray) and this mapping system. Typically, the procedure lasts from 3 to 6 hours.

In some instances, the physician determines that the VT may originate from a circuit on the outer surface of the heart,

or epicardium. If this is the case, a puncture into the sac, or pericardium, around the heart is performed just beneath the breastbone. This enables the ablation catheter to be inserted and maneuvered within the pericardium to determine whether the VT originates there. If a patient has a previous history of open heart surgery, a small surgical incision may be necessary to access the pericardium because of the presence of scar tissue, which can make the pericardium stick to the heart. These procedures to access the epicardium are usually performed at highly experienced centers.

Afterward, the catheters are removed, but the sheaths are left in until the blood thinner wears off. Typically, this



**Figure 2.** Mapping of VT. A 3-dimensional real-time map of the ventricle (created during the procedure) merged with a computed tomography scan (obtained before the procedure). The image shows the left ventricle (lower heart chamber), the aorta (the larger artery that receives the blood pumped by the heart), and the blood vessels on the surface of the heart. The purple areas represent normal heart muscle with normal voltage registered on contact mapping. The area with blue, yellow, and red indicates abnormal myocardium represented by progressively lower voltage, indicative of scar. Once a scar area is identified, the ablation is focused within and around this region. The white dots are the areas where ablation is performed within the scar.

requires the patient to lie still for several hours to prevent bleeding from the puncture sites. Slight discomfort and bruising in the groin area can occur, and some patients experience self-limited mild chest pain resulting from inflammation caused by the ablation lesions. When the procedure is successful, antiarrhythmic medications may be stopped at the discretion of the physician.

### What Are the Risks From the Procedure and Its Chance of Success?

Major risks of the procedure include stroke (less than 1%) or puncture of the heart with bleeding in the sac around the heart (pericardial effusion) requiring drainage with another catheter (1% to 2%). The risks of epicardial puncture include bleeding that can require surgery in less than 1% of procedures. If ablation is performed on the epicardium, damage to the coronary arteries, which can lead to a heart attack, is a potential risk. In these instances, a picture of the blood vessels on the surface of the heart (coronary angiogram) can be performed to minimize this risk.

The success of VT ablation varies, depending on the patient's specific heart condition that caused VT. The procedure is most effective in patients with otherwise normal hearts, in whom the success rate exceeds 90%. In patients with structural heart disease resulting from scar or cardiomyopathy, success rates range between 50% and 75% at 6 to 12 months. In cases when

a patient experiences a recurrence, 2 of 3 patients will still have less VT than before the initial ablation.<sup>2</sup>

### When Is Catheter Ablation an Appropriate Treatment?

Since radiofrequency catheter ablation was first described 20 years ago, it has played an increasing role in the treatment of ventricular arrhythmias. Initially used in the treatment of patients with multiple ICD shocks for VT (VT storm), it is now used more frequently and earlier in the management of VT, particularly in centers with a high volume of patients and experience. Catheter ablation is an excellent choice for patients when medications are not effective, tolerated, or preferred.

### Disclosures

Drs Tung, Boyle, and Shivkumar have received lecture honoraria from Boston Scientific, Biotronik, and St. Jude Medical, respectively. The University of California, Los Angeles has received grants from Biosense-Webster US and St. Jude Medical for its fellowship training program. Dr Shivkumar was supported by NHLBI (R01HL084261).

### References

1. Miller JM, Zipes DP. Catheter ablation of arrhythmias. *Circulation*. 2002;106:e203–e205.
2. Stevenson WG, Tedrow U. Preventing ventricular tachycardia with catheter ablation. *Lancet*. 2010;375:4–6.